



A study of evaluation of histopathological spectrum of lymph node lesions in a tertiary care centre

Dr. Shubhangi V Agale¹, Dr. Mukund B Tayade², Dr. Rachana Binayake³, Dr. Charu Sethi⁴, Dr. Grace F D'Costa⁵, Dr. Sachin Raut⁶

¹ Associate Professor, Department of Pathology, Grant Government Medical College, Sir J. J. Group of Hospitals, Mumbai, Maharashtra, India

² Dean Superintendent, Grant Government Medical College, Sir J. J. Group of Hospitals, Mumbai, Maharashtra, India

³ Associate Professor, Grant Government Medical College, Sir J. J. Group of Hospitals, Mumbai, Maharashtra, India

^{4,6} Resident, Department of Pathology, Grant Government Medical College, Sir J. J. Group of Hospitals, Mumbai, Maharashtra, India

⁵ Professor & Head, Department of Pathology, Grant Government Medical College, Sir J. J. Group of Hospitals, Mumbai, Maharashtra, India

Abstract

Objectives: Lymph nodes are involved in immune response of the body. The underlying cause of lymphadenopathy may range from a treatable infectious etiology to a malignant neoplasm. Excision biopsy of the lymph node provides material to establish an early diagnosis. The aim was to study the spectrum of pathological lesions of the lymph node and to find out the incidence with respect to age, sex and site. The study also aimed at histopathological subtyping of the malignant tumours in order to assess the prognosis.

Materials & Methods: Our study includes 170 lymph node biopsies. The sections were stained with H&E and special stains like AFB stain, reticulin and Masson's trichrome were done wherever needed.

Immunohistochemistry was performed in case of malignant lymphomas.

Results: Out of 170 biopsies received 114(67%) were from cervical region, 25(15%) from axilla, 20(11%) from inguinal, 9(5.7%) mesenteric and 2(1.3%) retroperitoneal.

Tuberculous lymphadenitis with 75(44.11%) cases was found to be the predominant lesion followed by reactive hyperplasia with 57(33.52%) cases. Amongst neoplastic disorders metastatic carcinomas with 13(7.64%) cases were found to be more common than primary lymphomas with 8(4.70%) cases. Viral lymphadenitis, dermatopathic lymphadenitis and Castleman's disease had equal incidence (2.94% each). Kikuchi's disease was found in only 2 cases. Non-neoplastic lesions were most common between 20-30 years whereas neoplastic lesions were more common between 50-60 years of age.

Conclusion: Non-neoplastic involvement of lymph nodes is much more common than neoplastic lesions with tuberculous lymphadenitis being the most common lesion irrespective of age and sex.

Keywords: lymph node, biopsy, non-neoplastic pathology, neoplastic pathology

Introduction

The lymph node plays an important role in retaining and reacting to foreign antigens, and lymph node changes reflect regional as well as systemic pathologic disorders. The degree and pattern of the morphologic changes are dependent on the inciting stimulus and the intensity of the response^[1,2].

The enlargement of the lymph node is common clinical finding, and can be due to neoplastic or non-neoplastic disorders^[3-9]. The clinically significant lymphadenopathy has a diameter of >1 cm (cervical, axillary), and >1.5cm for inguinal lymph nodes^[6].

The causes of non-neoplastic lymphadenopathy include reactive hyperplasia, infections (bacterial, viral, fungal), drug reactions (including certain vaccines), and a variety of miscellaneous non-neoplastic lymphoproliferative disorders^[4-9]. The neoplastic disorders are mainly lymphoid malignancies and metastases^[3,4].

The clinical history is invaluable in cases of lymphadenopathy and includes signs, symptoms, regional/generalised lymphadenopathy and hepato-splenomegaly^[6-8].

This study was undertaken to evaluate the different histomorphological patterns of lesions in lymph node biopsies and to find out the incidence of non- neoplastic and neoplastic

disorders with respect to site, age and sex.

Materials and methods

The present study was a prospective study carried out in the Department of Pathology, Grant Govt. Medical College and Sir J. J. Group of Hospitals, Mumbai over a period of 2 years. Our study included 170 lymph node biopsies received in 10% formalin in the department of pathology during that period.

Inclusion criteria

The study included 170 biopsied lymph node specimens.

Exclusion criteria

Cases where histopathological studies were inconclusive, due to the lack of adequate material, or other causes.

Relevant clinical history was noted from the histopathological requisition forms and case notes. Macroscopic findings were noted and the biopsies were totally submitted for routine processing. 3-4 micron thick sections were obtained from the paraffin blocks and routinely stained with Haematoxylin and Eosin. The stained slides were examined under light microscope and findings were noted.

Special stains like AFB stain, reticulin and Masson's

trichrome were done wherever needed. The statistical analysis of data was expressed as numerical and percentages. All biopsies were divided into 2 broad categories: non-neoplastic and neoplastic, and sub-grouped into specific diagnosis based on histopathological examination.

All lymphoma cases were classified according to the standard World Health Organization (WHO) classification of hemato-lymphoid malignancies.

Results

A total of 170 cases of lymph node biopsy were considered in the present study, which was carried out in the department of pathology of tertiary care centre.

Out of 170 biopsies received 114(67%) were from cervical region, 25(15%) from axillary region, 20(11%) from inguinal region, 9(5.7%) mesenteric and 2(1.3%) retroperitoneal region [Table 1] [Fig. 1].

The youngest patient was a 5 year old child and the oldest one was a 76 year old male with an average age at the time of presentation was 32.5 years. Non-neoplastic lesions were most common between 20-40 years whereas neoplastic lesions were more common between 50-60 years of age [Table 2][fig. 2]. Out of 170 cases, 98(57.65%) were males and 72(42.35%) were females with a M:F ratio of 1.3:1.

Histopathological examination was considered gold standard in this study. Cases were categorized into benign and malignant, which showed 149(87.65%) cases to be of benign etiology and 21(12.35%) cases to be of malignant etiology [Table 3].

Histopathological examination revealed tuberculous lymphadenitis [Fig. 4] to be the most predominant lesion with 75(44.11%) cases followed by reactive hyperplasia with 57(33.52%) cases. Amongst neoplastic disorders metastatic carcinomas were found to be more common (13 cases, 7.64%), than primary lymphomas [Fig. 5] with (8 cases, 4.70%). Viral lymphadenitis, Castleman’s disease [Fig. 6, Fig. 7] and dermatopathic lymphadenitis [Fig. 8] had equal incidence of 5(2.94%) cases each. Kikuchi’s disease [Fig. 9] was found in only 2 cases [Table 4] [fig. 4].

In case of metastatic carcinomas, the primary site of malignancy included breast in 3(23.07%) cases, colon in 3(23.07%) cases, oral cavity in 2(15.38%) cases and stomach and thyroid in 1(7.69%) case each. In the remaining 3 cases

the primary site of malignancy was unknown [Table 5].

Out of the 8 cases of primary lymphomas, 5 cases were of non-Hodgkin’s lymphoma and 3 cases were of Hodgkin’s lymphoma.

Out of the 134 cases clinically diagnosed as benign, 128 cases were diagnosed to be benign on histopathological examination. Conversely out of the 36 cases clinically diagnosed as malignant, 15 were malignant on histopathological examination [Table 6].

In comparing the accuracy of clinical diagnosis to histopathology, with respect to the determination of benign and malignant lesions, the sensitivity was 71.42%, whereas specificity was 85.90%. Positive predictive value was at 41.66 %.The negative predictive value was 95.52%.Thus the accuracy of clinical diagnosis when compared to histopathological examination was 84.11%.

Table 1: Site wise distribution of cases in study group

Sr. No	Site	Number Of Cases	Percentage[%]
1.	Cervical	114	67.05
2.	Axillary	25	14.70
3.	Inguinal	20	11.76
4.	Mesenteric	9	5.29
5.	Retroperitoneal	2	1.20
Total		170	100

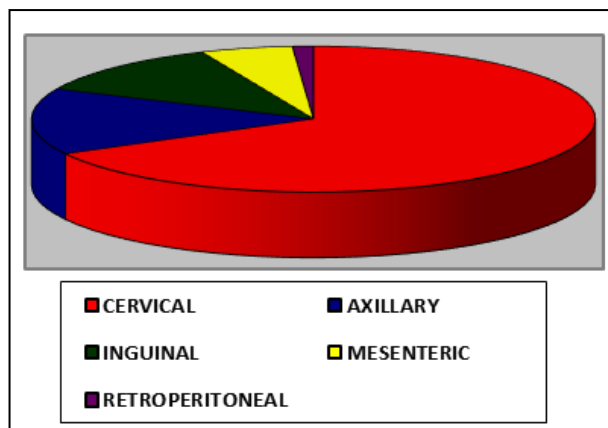


Fig 1: Site wise distribution of cases in study group

Table 2: Age wise distribution of cases in the study group

Age Group	Tuberculous Lymphadenitis	Reactive Hyperplasia	Viral Lymphadenitis	Dermatopathic Lymphadenitis	Castleman’s Disease	Kikuchi’s Disease	Metastatic Carcinoma	Primary Lymphoma
0-10	3	5	-	-	-	-	-	-
11-20	15	11	-	1	-	-	-	1
21-30	19	13	1	2	2	1	1	1
31-40	16	10	3	1	-	1	2	1
41-50	11	10	1	1	2	-	2	2
51-60	8	4	-	-	1	-	5	2
61-70	3	3	-	-	-	-	2	1
71-80	-	1	-	-	-	-	1	-
Total	75	47	5	5	5	2	13	8

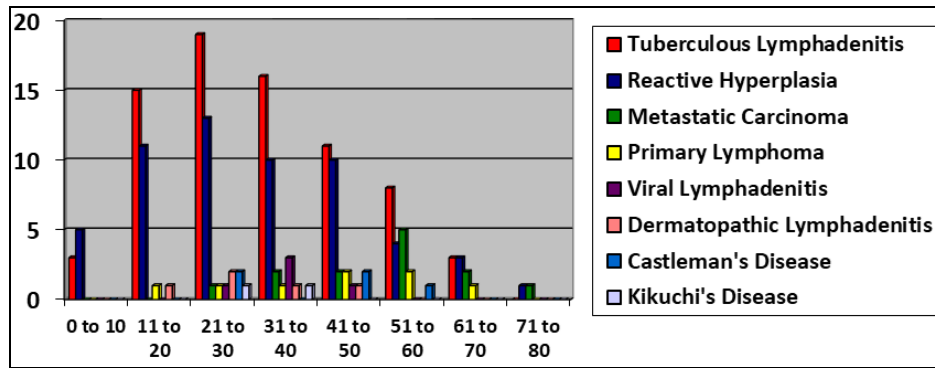


Fig 2: Age wise distribution of cases in the study group

Table 3: Histopathologically benign and malignant categories.

Histopathological Findings	Number of cases	Percentage (%)
Benign	149	87.65
Malignant	21	12.35
Total	170	100

Table 4: Histopathological finding wise distribution of cases in the study group

Sr. No	Diagnosis	Number Of Cases	Percentage[%]
1.	Tuberculous Lymphadenitis	75	44.11
2.	Reactive Hyperplasia	57	33.52
3.	Metastatic Carcinomas	13	7.64
4.	Primary Lymphomas	8	4.70
5.	Viral Lymphadenitis	5	2.94
6.	Dermatopathic Lymphadenitis	5	2.94
7.	Castleman's Disease	5	2.94
8.	Kikuchi's Disease	2	1.21
Total		170	100

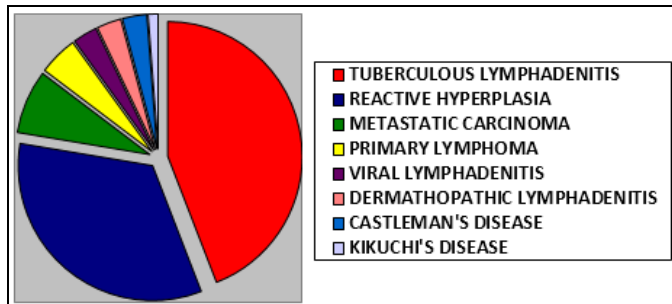


Fig 3: Histopathological finding wise distribution of cases in the study group

Table 5: Primary site of malignancy and the histopathological diagnosis

Primary Site of Malignancy	Histopathological Diagnosis	Number of Cases
Breast	Infiltrating ductal carcinoma	3
Colon	Adenocarcinoma	3
Oral Cavity	Squamous cell carcinoma	2
Thyroid	Papillary carcinoma	1
Stomach	Adenocarcinoma	1
Unknown	Squamous cell carcinoma Adenocarcinoma	3

Table 6: Association between the clinical diagnosis and the histopathological findings in the study group

Clinical Diagnosis	Histopathological Findings		Total
	Malignant	Benign	
Malignant	15	21	36
Benign	6	128	134
Total	21	149	170

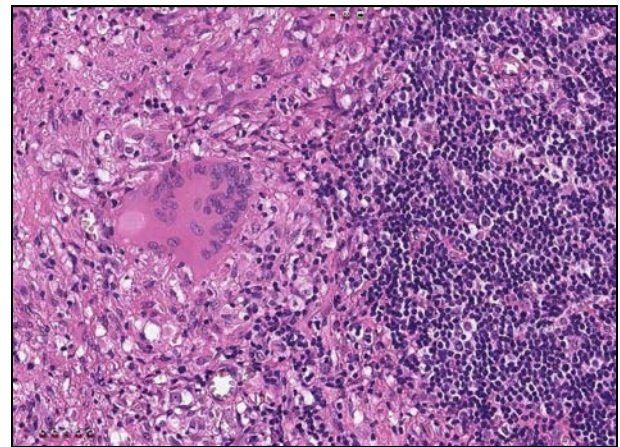


Fig 4: Tuberculous Lymphadenitis: Micro-photograph showing well formed epithelioid cell granuloma comprising of epithelioid cells, Langhan's giant cell and lymphocytes (H&E, x400)

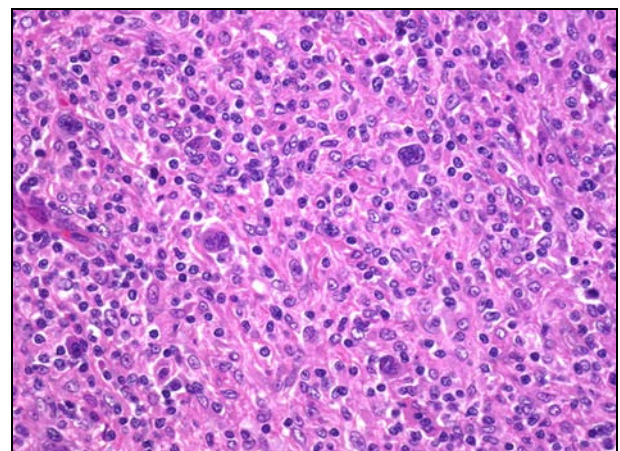


Fig 5: Hodgkin's Lymphoma: Micro-photograph showing Reed-Sternberg cells against a polymorphous background (H&E, x400)

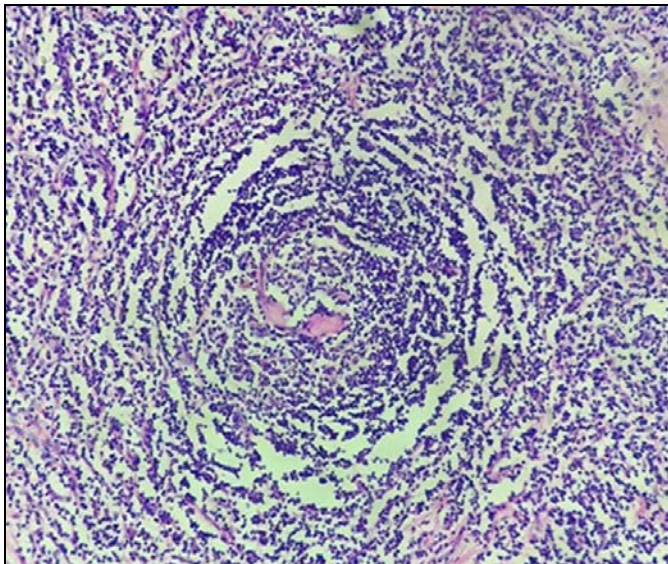


Fig 6: Hyaline vascular variant of Castleman’s disease: Micro-photograph showing regressed germinal centre radially penetrated by hyalinised blood vessel (lollipop follicle) (H&E, x200)

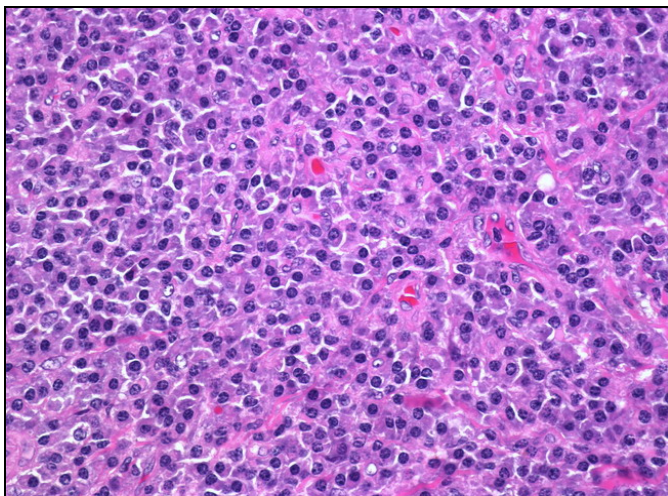


Fig 7: Plasma cell variant of Castleman’s disease: Micro-photograph showing plasma cells in the interfollicular region (H&E, x400)

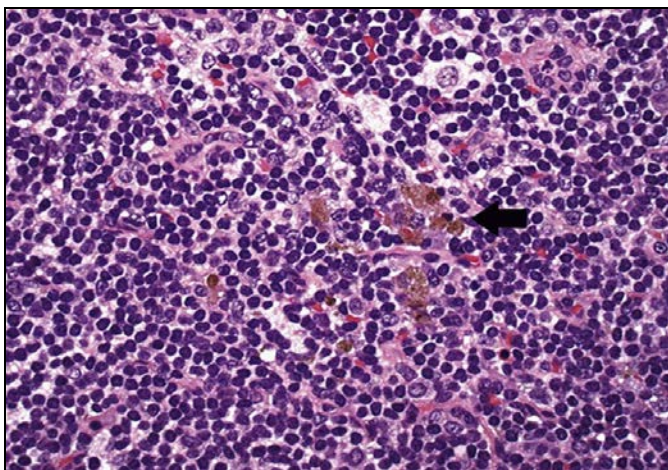


Fig 8: Dermatopathic lymphadenitis: Micro-photograph showing macrophages containing melanin pigment (H&E, x400)

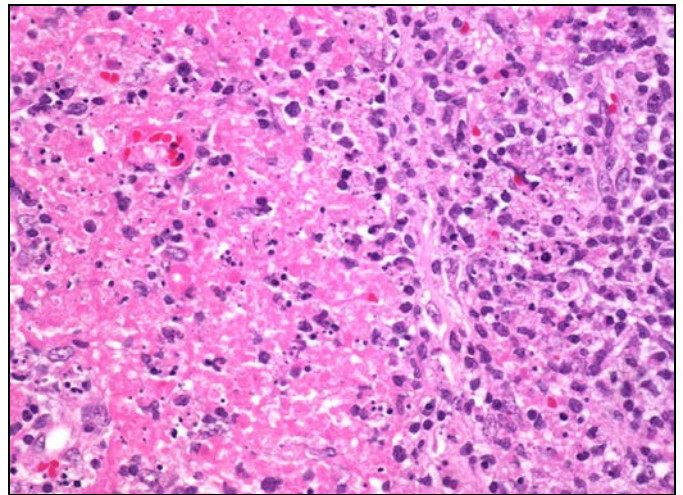


Fig 9: Kikuchi’s disease: Micro-photograph showing large area of necrosis along with apoptotic cells and nuclear debris (H&E, x400)

Discussion

The lymph nodes are widely distributed and easily accessible lymphoid tissue in the body, which are frequently examined and biopsied for diagnostic purpose. The lymph nodes are the most important component of immune system and lymphadenopathy may be the first symptom of various disorders [2, 13, 14]. The condition “Lymphadenopathy” refers to nodes that are abnormal in size, consistency or number. Clinically it can be classified as 1. Generalized lymphadenopathy- if the lymph nodes are enlarged in two or more non-contiguous areas. 2. Localized lymphadenopathy- if only one area is involved [12, 13].

Usually the size and texture of the lymph nodes and the presence of pain/ tenderness are useful parameters in evaluating a patient with lymphadenopathy. Nodes <1.0 cm in diameter (1.0 cm x 1.0 cm or less) are almost always due to benign, nonspecific reactive causes [13].

The histopathological examination of the lymph node remains the ‘Gold standard’ for diagnosis of lymph node Diseases [2, 14]. It is essential to confirm the lymph node lesion to identify the exact etiology to decide and plan an appropriate treatment modality.

In our study, the maximum number of lymph node biopsies were from cervical group of lymph nodes (67%) which is more than the study done by Pagaro *et al.* [10] (39%), Albasri *et al.* [11] (37%) but is less than the study done by Thapa *et al.* [5](70%) and Gupta *et al.* [4] (79.17%). The axillary lymph node involvement was 14.70% in our study which is comparable with Gupta *et al.* [4] study(18.33%) but inguinal lymph node involvement (11.76%) was more as compared to Gupta *et al.* [4] (2.50%) study.

The age of the patients ranged from 5 years to 76 years with mean age of presentation being 32.5 years which is comparable with study done by Albasri *et al.* [11] who had age range of 2.5 to 96 years with mean of 33.9 years and Gupta *et al.* [4] who had age range of 1.5 years to 70 years with average age of 30.72 years. Kamat GC [12] study had most cases in the age group 11-20 years (71 cases, 29.09%), and the least cases in the age group over 70 years (four cases, 1.64%).

Non-neoplastic lesions were most common between 20-40

years (69 cases) which is similar to Vidyadhar *et al.* [2] study (46 cases-30.26%) whereas neoplastic lesions were more common between 50-60 years of age.

In our study, 98 cases (57.65%) were males and 72 cases (42.35%) were females with a M:F ratio of 1.3:1 which is in concordance with the study of Panchal *et al.* [9]. (M:F-1.3:1). Gupta *et al.* [4]. had M:F ratio of 1.73:1, which is slightly more than our study. Male predominance was also observed in the study by Roy *et al.* [3], and Albasri *et al.* [11]; but female predominance was found in the study by Vidyadhar *et al.* [2]. (M:F-1:1.79), AL-Ali *et al.* [8]. (M:F-1:1.4), and Damle *et al.* [1]. (M:F-1:1.4).

This study showed 149(87.65%) cases to be benign and 21(12.35%) cases to be malignant which is similar to Kamat GC [12] study with 88.92% benign cases and 11.08% malignant cases. Similar results were also seen in study by Halder *et al.* [13] and AL-Ali *et al.* [8]; but malignant lesions were more common in the study done by Roy *et al.* [3], Albasri *et al.* [11] and Özkan *et al.* [14]

Tuberculous lymphadenitis was the predominant lesion in present study with 75(44.11%) cases which was in concordance with the study of Gupta *et al.* [4] (40%) and Suba *et al.* [7] (42.7%). The second most common category was reactive hyperplasia accounting for 57(33.52%) cases, similar findings were observed by Suba *et al.* [7] (39.8%) and Kamat GC [12] (30.73%). Other studies showing reactive hyperplasia as the second most common category were Panchal *et al.* [9] and Albasri *et al.* [11]

Amongst neoplastic disorders metastatic carcinomas with 13(7.64%) cases were found to be more common than primary lymphomas with 8(4.70%) cases. Similar findings were observed by Kamat GC [12] with 7.37% cases of metastatic carcinomas and 3.67% cases of primary lymphomas. Vidyadhar *et al.* [2] found 19.9% metastatic carcinoma cases and 3.98% primary lymphoma cases.

Our study showed more cases of Non-Hodgkin's lymphoma than Hodgkin's lymphoma which is similar to the study done by Vidyadhar *et al.* [2], Roy *et al.* [3] and Panchal *et al.* [9].

Conclusion

This study highlights the usefulness of lymph node biopsy in diagnosis of lymph node diseases, in patients presenting with lymphadenopathy. The lymph node biopsy is easy and inexpensive tool for the diagnosis of non- neoplastic and neoplastic disorders of lymph node and systemic diseases.

References

- Damle RP, Suryawanshi KH, Dravid NV, Newadkar DV, Deore PN. A Descriptive Study of Histopathological Patterns of Lymph Node Biopsies in A Tertiary Care Hospital. *Annals of Pathology and Laboratory Medicine.* 2017; 4(2):A131-136.
- Vidyadhar R, Prakash CSR, Philip KS. Histopathological study of lymph node lesions. *Journal of International Medicine and Dentistry.* 2015; 3:24-33.
- Roy A, Kar R, Basu D, Badhe BA. Spectrum of histopathologic diagnosis of lymph node biopsies: a descriptive study from a tertiary care center in South India over 5½ years. *Indian J Pathol Microbiol.* 2013; 56(2):103-8.
- Gupta N, Agarwal P. Spectrum of pathological lesion in superficial lymphnodebiopsy in a tertiary health centre of western Rajasthan. *IOSR J of Dent and Med Sci.* 2016; 15(11):62-65.
- Thapa S, Ghosh A, Ghartimagar D, Narasimhan R, Prasad T, Talwar OP. Histopathological analysis of non-neoplastic superficial lymphadenopathies. *Kathmandu Univ Med J (KUMJ).* 2017; 15(57):51-55.
- Tanteo MC, Garcia RD. Clinical profile and histopathologic diagnoses of childhood peripheral lymphadenopathy: an MMC experience. *PIDSP Journal.* 2011; 12(2):67-74.
- Suba G, Jayaprakash HT, Shradha A. Morphological spectrum of peripheral lymphadenopathy–A hospital based study. *Indian Journal of Pathology and Oncology.* 2017; 4(2):278-81.
- AL-Ali ZA. Patterns of lymph node pathology using biopsy evaluation tool for lymphadenopathy: a retrospective descriptive study conducted at Al Hussein Medical City 2014–2016. *Iraq Medical Journal.* 2017; 1(4):102-105.
- Panchal J, Pai P. Spectrum of pathologic lesions in superficial lymph node biopsies—a one and half year study. *International Journal of Biomedical and Advance Research.* 2014; 5(9):435-8.
- Pagaro PM, Banerjee B, Khandelwal A, Pandey A, Gambhir A. Spectrum of lymph node lesions as determined by histopathology. *Med J DY Patil Univ.* 2017; 10:343-8.
- Albasri AM, El-Siddig AA, Hussainy AS, Alhujaily AS. Pattern of lymph node pathology in western Saudi Arabia. *Asian Pac J Cancer Prev.* 2014; 15(11):4677-81.
- Kamat GC. A ten-year histopathological study of generalized lymphadenopathy in India. *S Afr Fam Pract* 2011; 53(3):267-270.
- Halder S, Saha BK, Sarkar D, Ghosh S. Etiological study of generalized lymphadenopathy in a tertiary care hospital. *International Journal of Research in Medical Sciences.* 2017; 4(8):3542-8.
- Özkan EA, Göret CC, Özdemir ZT, Yanık S, Göret NE, Doğan M, *et al.* Evaluation of peripheral lymphadenopathy with excisional biopsy: six-year experience. *International journal of clinical and experimental pathology.* 2015; 8(11):15234.